

---

# THE MITRAL VALVE

## A Pluridisciplinary Approach

---

**Daniel Kalmanson, M.D., Editor**  
Fondation Adolphe de Rothschild  
Department of Cardiology

Chief, Cardiac Surgery  
Department, Western Heart  
Associates, San Jose, California

**D.W. Baker, DSEE**

Associate Professor

Center for

University

Seattle, Washington

**A.C. Beall, Jr., M.D.**

Professor of Surgery, Chief,  
Department of Surgery, Baylor  
College of Medicine, Texas  
Medical Center, Houston, Texas

**E.J. Beilhouse, M.A., D.Phil.**

Department of Engineering  
Science, University of Oxford,  
Oxford, England

**V.O. Björk, M.D.**

Professor, Department of Thoracic  
and Cardiovascular Surgery,  
Karolinska-Sjukhuset, Thoracic  
Surgical Clinic, Stockholm,  
Sweden

**D. Borkehnagen, M.D.**

Harvard Medical School, Boston,  
Massachusetts

**C. Cabreria, M.D.**

Professor, Chief, Department of  
Thoracic and Cardiovascular Surgery,  
Hospital General de Ginebra, Ginebra,  
Switzerland

**J.P. Cochran, M.D.**

Associate Professor, Department of  
Surgery, University of Wisconsin,  
Madison, Wisconsin

**A. Deloche, M.D.**

Associate Professor, Clinique de  
Chirurgie Cardiovasculaire,  
Hôpital Bicêtre, Paris, France

**R.T. Dodge, M.D.**

Professor of Medicine, University  
of Washington, Seattle,  
Washington

**Ch. Dubost, M.D.**

Professor, Director,  
Hôpital Cochin, Paris, France

**C.M.G. Duran, M.D., D.Phil.**

Professor, Chief, Centro Médico  
Nacional "Marques de  
Valdecilla," Santander, Spain

**J.D. Fols, Ph.D.**

Associate Professor, Department  
of Medicine, University of  
Wisconsin, Madison, Wisconsin

**Publishing Sciences Group, Inc.**

Acton, Massachusetts

a subsidiary of CHC Corporation

# 45 Plastic and Reconstructive Mitral Valve Surgery

Alain Carpentier, M.D.

Mitral valve surgery began in 1965 with the attempts of Lillehei, Murray, and others to repair the mitral valve apparatus by a direct approach under extracorporeal circulation.<sup>13</sup> Following these pioneering efforts, several techniques were developed to correct mitral insufficiency either isolated or combined with stenosis. Pure mitral insufficiency was corrected by techniques which reduced the size of the orifice area by commissural plication,<sup>15,17,19</sup> semicircular sutures,<sup>3</sup> or by suturing a pledget of Teflon to the annulus at the mural leaflet.<sup>15</sup> Stenotic lesions were treated by commissurotomy and splitting of the chordae tendineae.<sup>12,15</sup>

These techniques were progressively abandoned for several reasons: first, because they failed to achieve a regular and predictable result,<sup>4,12</sup> second, because they were associated with a high incidence of recurrent mitral insufficiency or stenosis,<sup>2,4</sup> and third, because suitable artificial prostheses became available.

The valvular prostheses, however, still involve thromboembolic problems and a persistent need for anticoagulation, two factors which affect the quality of life of the patient. This should stimulate us to



review our policy with regards to mitral valve repair, the more so since progress made in extracorporeal circulation and myocardial protection allows us to perform more sophisticated techniques.

The purpose of this paper is to state the principles which should serve as guidelines for plastic and reconstructive surgery of the mitral valve, and to present techniques which have been developed according to these principles.

## FUNDAMENTALS OF CONSERVATIVE MITRAL VALVE SURGERY

The aim of a plastic repair of the mitral valve is to restore valvular function to normal for the longest possible period. The problem therefore is to determine which lesions are suitable for such a repair and which techniques should be used. As we have shown earlier (Chapter 9), mitral insufficiency may be the result of multiple lesions affecting the different structures of the valvular apparatus: annulus, leaflet, tissue, commissures, chordae tendineae, papillary muscles, and the corresponding myocardial wall. Therefore a reconstructive operation should include multiple techniques directed towards all of the different lesions. These techniques were developed according to four basic principles: easy reproducibility, low operative risk, predictability of the result, and stability of the repair.

The reproducibility depends in part upon the complexity of the technique, and in part upon the effort of the surgeon to acquire the necessary experience. It must be accepted that the time required for carrying out the repair be longer than that of a valve replacement, and should not increase the operative risk. This depends upon the excellence of the by-pass technique and of myocardial protection during the operation.

The predictability of the result is one of the most difficult aims to achieve. It means that when leaving the operating room, the surgeon should ascertain that the repair he has performed will assume an excellent hemodynamic function.

Both predictability and long-term stability of the result depend upon the quality of the surgical repair: that is, the ability of the techniques to restore the anatomy and the physiology of the valvular apparatus as close to normal as possible.

## TECHNIQUES

### Repair of annular lesions

Dilatation of the annulus fibrosis is generally considered to be the major factor in mitral insufficiency. This is partially true, since the



review our policy with regards to mitral valve repair, the more so since progress made in extracorporeal circulation and myocardial protection allows us to perform more sophisticated techniques.

The purpose of this paper is to state the principles which should serve as guidelines for plastic and reconstructive surgery of the mitral valve, and to present techniques which have been developed according to these principles.

## FUNDAMENTALS OF CONSERVATIVE MITRAL VALVE SURGERY

The aim of a plastic repair of the mitral valve is to restore valvular function to normal for the longest possible period. The problem therefore is to determine which lesions are suitable for such a repair and which techniques should be used. As we have shown earlier (Chapter 9), mitral insufficiency may be the result of multiple lesions affecting the different structures of the valvular apparatus: annulus, leaflet, tissue, commissures, chordae tendineae, papillary muscles, and the corresponding myocardial wall. Therefore a reconstructive operation should include multiple techniques directed towards all of the different lesions. These techniques were developed according to four basic principles: easy reproducibility, low operative risk, predictability of the result, and stability of the repair.

The reproducibility depends in part upon the complexity of the technique, and in part upon the effort of the surgeon to acquire the necessary experience. It must be accepted that the time required for carrying out the repair be longer than that of a valve replacement, and should not increase the operative risk. This depends upon the excellence of the by-pass technique and of myocardial protection during the operation.

The predictability of the result is one of the most difficult aims to achieve. It means that when leaving the operating room, the surgeon should ascertain that the repair he has performed will assume an excellent hemodynamic function.

Both predictability and long-term stability of the result depend upon the quality of the surgical repair: that is, the ability of the techniques to restore the anatomy and the physiology of the valvular apparatus as close to normal as possible.

## TECHNIQUES

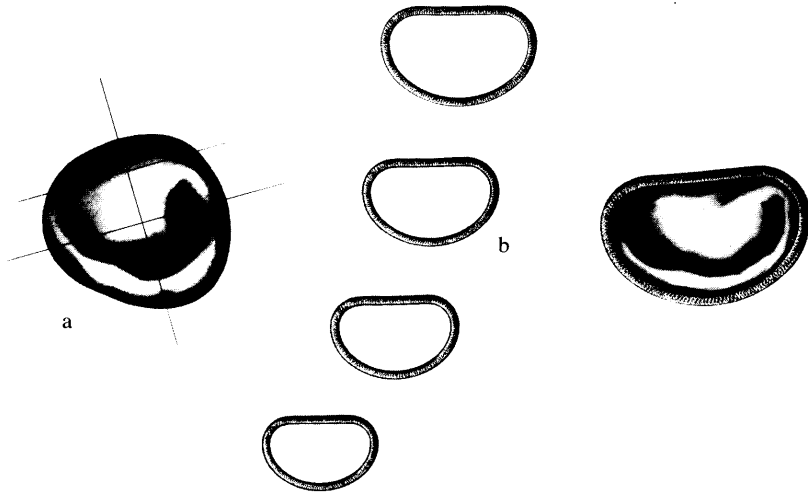
### Repair of annular lesions

Dilatation of the annulus fibrosis is generally considered to be the major factor in mitral insufficiency. This is partially true, since the

deformation of the annulus is at least as important as the dilatation (Fig. 1). The dilatation mainly affects the mural leaflet and the commissure. The anterior leaflet portion of the annulus is not affected in the same way because of its continuity with the aortic root. The deformation may be symmetrical or asymmetrical. In symmetrical dilatation, the anteroposterior diameter of the orifice is greater than the transverse diameter, and both commissures are equally enlarged (Fig. 1). Asymmetrical deformation may result from the enlargement of the anterior commissure or of the posterior commissure. In reconstruction of the mitral valve annulus, not only must the annulus be reduced to its physiologic dimensions, but the commissures must be remodelled as well in order to restore their physiologic curvature. The use of suitably shaped and sized prosthetic rings makes it possible to accomplish each of these corrections accurately and permanently.<sup>6</sup>

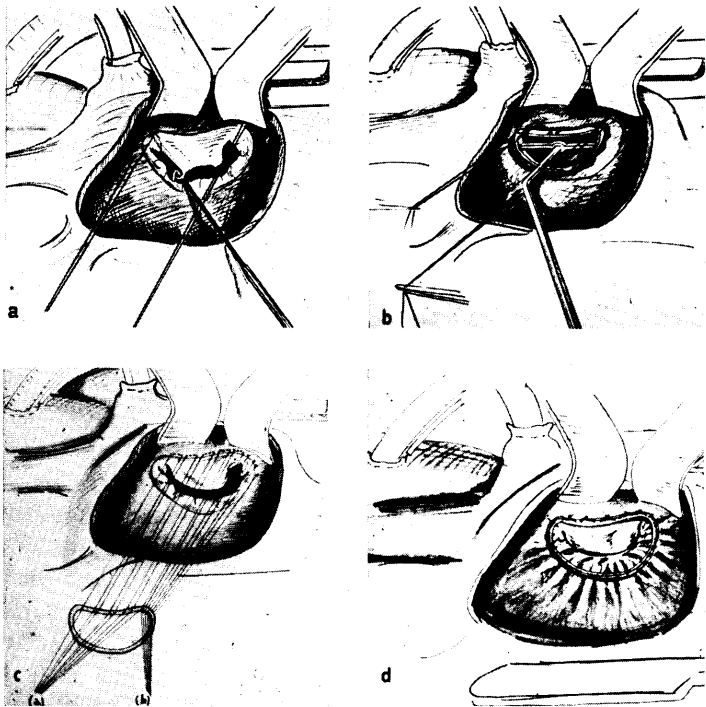
The size of the rings and their corresponding interior areas are as follows: 26 mm (3.05 cm<sup>2</sup>), 28 mm (4.09 cm<sup>2</sup>), 30 mm (4.85 cm<sup>2</sup>), 32 mm (5.19 cm<sup>2</sup>), 34 mm (5.50 cm<sup>2</sup>), 36 mm (5.78 cm<sup>2</sup>). Each ring is made of stainless steel and covered with a fine polyester fabric which favors the incorporation of the prosthesis.

The choice of the ring is based on the measurement at the base of the aortic leaflet, which is not affected by the annulus dilatation, and therefore can be used as a guide for the determination of the



**Figure 1.** Concept of mitral annulus remodeling. (a) Annulus dilatation is associated with annulus deformation. Dilatation affects mainly the commissures and the annulus at the mural leaflet. Deformation is such that the antero-posterior diameter becomes greater than the transverse diameter. It may be symmetrical or asymmetrical. (b) Suitably shaped and sized prosthetic rings permit the remodeling of the orifice, respecting the normal motion of the leaflet and the commissures.

physiologic dimensions of the mitral orifice. In order to facilitate this measurement, one suture is placed at each commissure (Figure 2a). The distance between these two points is measured with the obturators (Figure 2b). Approximately 15 sutures are placed through the annulus along the whole periphery of the mitral ring. These are then passed through the sewing ring of the prosthesis. The same space interval must be maintained between sutures of the aortic leaflet and their point of insertion into the corresponding portion of the prosthesis. Spacing is reduced for the sutures of the posterior leaflet. If there is an asymmetric dilatation of the annulus with a predominant enlargement of one commissure, the distribution of the sutures must obviously be adapted: the spacing of the sutures must be especially reduced in the corresponding area of the prosthetic ring (Figure 2c). The ring is then brought into position and the sutures tied. This repositions the different annular structures without reducing the normal orifice area or affecting leaflet motion (Figure 2d).



**Figure 2.** Technique of ring insertion. (a) pilot sutures placed at each commissure; (b) measurement by obturators of distance between commissures; (c) spacing of sutures on prosthetic ring parallel for aortic leaflet sutures, reduced for sutures of the remainder of the annulus; (d) sutures tied, ring in place.

One criticism which can be leveled at such a repair of the mitral annulus is the rigidity of the prosthetic ring. This is a somewhat theoretical disadvantage, since in mitral insufficiency, the annulus is irreversibly damaged and not capable of contraction during systole. However, a flexible ring has been developed and used in the last year, both in the mitral and the tricuspid areas,<sup>7</sup> to evaluate possible advantages regarding long-term function. The flexibility of the ring is selective: the transverse diameter can be increased but not decreased; the anteroposterior diameter can be decreased 30% of its normal length, but not increased, and the commissures do not modify their shape during systole (Fig. 3). This permits retention of the remodelling effect the mitral annulus.

### Repair of commissural fusions

Fusion of the commissures may be divided into three grades as to severity of lesions. Grade I corresponds to partial fusion of the commissures ( $\leq 5$  mm), with preservation of the commissural chordae. The commissurotomy in this case is easy to perform since the commissure is well delineated and the chordae well individualized. The incision is made between two chordae and extends to within no more than 3 mm from the annulus.

Grade II corresponds to complete fusion of the commissures, with a still well defined border appearing as a furrow between the anterior and the mural leaflet. Small calcifications may be present. Chordae may be fused. Because of the still visible commissural line, commissurotomy is not a difficult maneuver, and the result is generally excellent because the edges of the anterior and posterior leaflets still have a surface of coaptation. It may be necessary to remove some

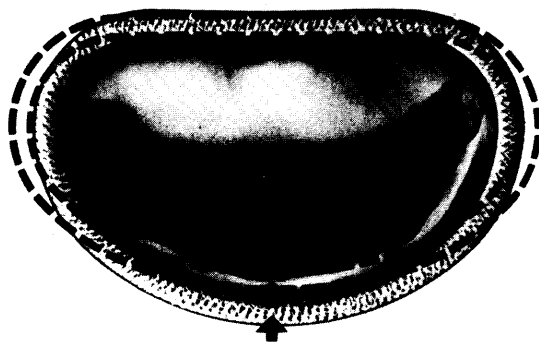

Figure 3. Flexible ring. Dashed line represents the shape of the ring at systole.

calcifications and to split fused chordae to mobilize the leaflets and prevent early refusion of the commissure.

Grade III corresponds to complete fusion of the commissures, with no delineation between the anterior and the posterior leaflets. There is continuity between both leaflets at the level of the commissures. Commissural chordae are often fused, so that it is difficult to know exactly where to perform the commissurotomy. The site and direction of the commissure may be defined as a line joining the attachment of the main chordae of the anterior leaflet to the fibrous trigone.

### Repair of valvular lesions

The leaflet tissue may be affected by different lesions such as: perforation, cleft formation, thickening, valve shrinkage, or calcification. A careful analysis of the nature, the site, the extent, and the severity of the lesions leads to a judgment regarding conservation of the valve rather than replacement.

*Perforation* of the mural leaflet may be treated by cuneiform resection of the leaflet and subsequent suture of the remaining edges. Only small perforations ( $\leq 5$  mm) of the anterior leaflet may be treated by resection and subsequent suture.

*Valve thickening*, a consequence of rheumatic valve disease, generally does not overly affect the pliability of the leaflets. It may be localized, having the aspect of a fibrous nodule or a fibrous band, which should be either resected or thinned. It may be more extensive and due to hypertrophic intermediary chordae which should be resected. If the pliability of the valve is significantly altered by the fibrous process, the valve should be replaced.

Only *localized calcifications* can be treated by conservative techniques, such as resection of the calcified area and subsequent suture (Fig. 4a).

### Repair of subvalvular lesions

The subvalvular apparatus may present different lesions of various etiologies:

Ruptured papillary muscle secondary to myocardial infarction.

Ruptured chordae due to either bacterial endocarditis, degeneration of the chordae, or rheumatic valve disease.



Elongated chordae due to chordae dysplasia or rheumatic process.

Fusion and retraction of the chordae.

In most instances, the three latter types of lesions can be treated by conservative procedures.

*Ruptured chordae* are treated by resection of the prolapsed part of the valve and suturing of the remaining edges. Resection is preferred to a McGoon type of plication, which may lead to progressive retraction and thickening of the infolded part. A quadrangular resection is preferable in order to avoid excess tension on the free edge of the leaflet, a consequence of triangular resection (Fig. 4 b). Valvular replacement may be necessary if the rupture affects the main chordae of the aortic leaflet.

*Elongation of chordae* is treated by the following technique: the extremity of the corresponding papillary muscle is longitudinally incised. The excess length of the chordae is firmly attached by closing the papillary muscle around the buried portion of the chordae (Fig. 4 c).

*Fused chordae* are treated by incision of the chordae or by resection of a triangular portion of the scar tissue in order to completely release the subvalvular stenosis. Those hypertrophic and shortened intermediary chordae arising from the inferior surface of the leaflets and not from their free margins are resected (Fig. 4 d).

## CLINICAL EXPERIENCE

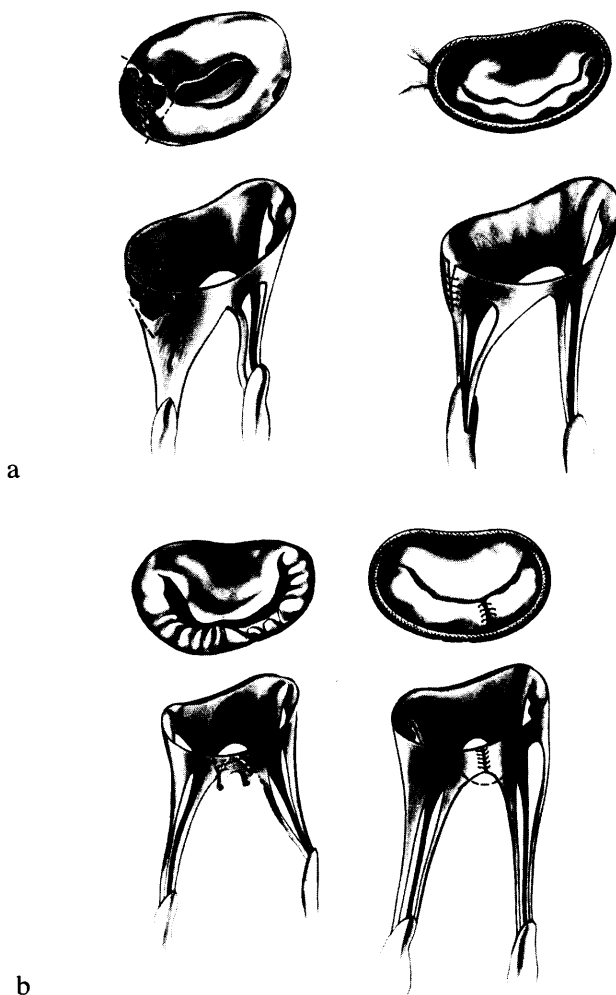
These different techniques are the result of an evolution of the author's experience in mitral valve surgery during the past seven years. In the beginning, attention was focused on pure mitral insufficiency due to annular lesions which could accurately be treated by ring valvuloplasty. This group represented only 4% of open heart mitral valve lesions encountered at surgery. Since remodelling of the valve appeared not to reduce the normal orifice area, valvular reconstruction could be extended to the treatment of more complex lesions. These included combined mitral insufficiency and stenosis, which was heretofore considered to be a contraindication to reconstructive procedures. Thus, the great majority of noncalcified mitral valve disease, which accounted for 40% of the open-mitral valve cases in our experience, has been treated by such conservative procedures in the past few years.

**Material (Table 1)**

Our experience at the Broussais Hospital\* between September 1968 to December 1974 consists of 330 mitral valve repairs. Lesions were divided into three groups:

---

\* Surgical team: C. Dubost, C. D'Allaines, P. Blondeau, A. Piwnica, R. Soyer, and A. Carpentier

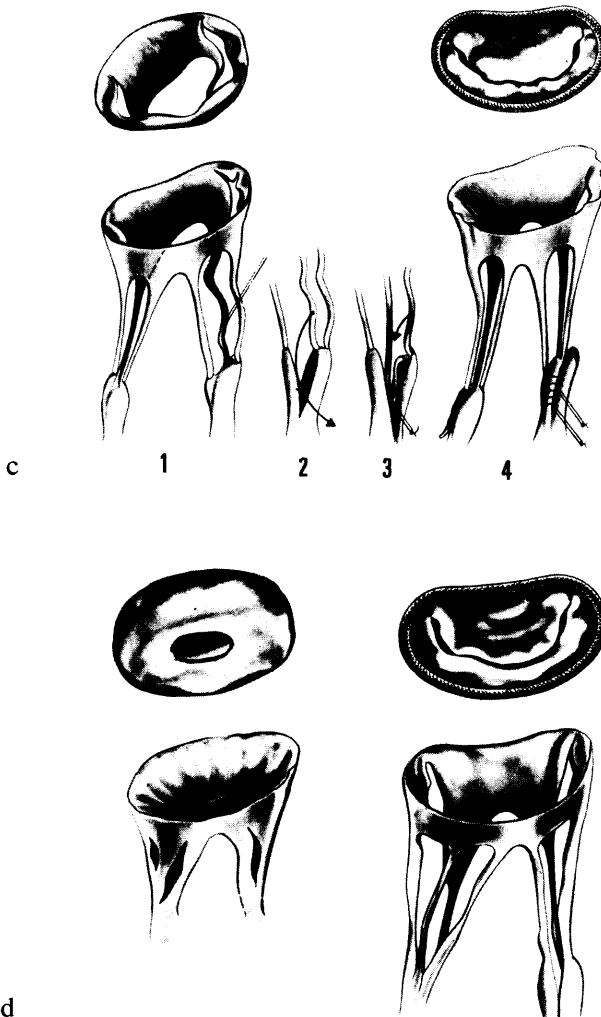


**Figure 4, a and b.** (a) Resection of calcification; (b) quadrangular resection of prolapsed portion of posterior leaflet secondary to ruptured chordae tendineae.

Group I: Pure mitral insufficiency without lesions of subvalvular structures.

Group II: Pure mitral insufficiency with lesions of subvalvular structures.

Group III: Combined insufficiency and stenosis.



**Figure 4, c and d.** (c) Shortening of elongated chordae tendineae: 1, elongated chorda; 2, incision of papillary muscle; 3, extra length of the chorda is buried in the papillary muscle; 4, closure of papillae (d) fenestration of fused chordae tendineae.



**Table 1**  
**Material and Surgical Treatment**

---

Group I:	pure mitral insufficiency (prosthetic ring): 93
Group II:	mitral insufficiency + Sub-valvular lesions: 85
	a) ruptured chordae (ring + Valve resection): 42
	b) elongated chordae (ring + Chordae shortening): 34
	c) fused chordae (ring + chordae fenestration and resection): 9
Group III:	mitral insufficiency and mitral stenosis: 152
	a) noncalcified (ring + commissurotomy + chordae fenestration and resection): 136
	b) calcified (ring + commissurotomy + chordae fenestration and resection + Calcium removal): 16
	Total: 330

---

Group I consisted of 93 cases treated by remodelling of the annulus with a prosthetic ring. Group II consisted of 85 cases of which 42 had ruptured chordae treated by valvular resection, and 34 had elongated chordae treated by shortening of the chordae; 9 had both lesions. Group III consisted of 152 cases treated by commissurotomy, annulus remodelling, and treatment of subvalvular lesions: elongated chordae, hypertrophic chordae, fused chordae.

The average age of the patients was 37 years, ranging from 12 to 72 years (mitral valve surgery in children being excluded from this study). Rheumatic disease was responsible for the valvular lesions in 248 patients, bacterial endocarditis in 24, and nonrheumatic dystrophic or degenerative disease in the remaining 58. According to the New York Heart Association Classification, 212 patients (63%) were in Class IV, 110 (35%) in Class III, and 8 in Class II (2%).

## Results (Table 2)

There were 29 (9%) operative deaths in the whole series. Operative mortality was somewhat higher in the early period (15.5%) due to technical errors; it has been reduced to 4% in the last 100 patients. Causes of death were: injury to the circumflex artery in our early experience (2), infection (3), myocardial infarction (5), anemia (2), air embolism (2), and low cardiac output (10). Late death occurred in 9 patients (3%) followed for 1 to 7 years after the operation (average follow-up 3.2 years). Causes of late death were: persistent or recurrent mitral valve disease (5), cardiac failure (1), noncardiac (2), and unknown (1). The survival curve shows an 87% survival at 6 years (Figure 5).

**Table 2**  
**Results for 330 Patients (1968-1974)**

Hospital deaths	29	9%
Late deaths*	9	3%
- Valve related - (5-1.5%)		
Reoperations*	10	3.5%
Thromboembolism*	2	0.5%
Poor result*	4	1%
Good result*	260	92%

\*Long-term follow up available in 285 patients 1 to 7 years after operation (Average 3.2 years). Percentages based on 285 patients.

Long-term follow-up data are available for 285 patients. Reoperation was necessary in 9 patients (2.7%) because of disinsertion of the ring (3 patients), persistent mitral valve disease (4 patients), and recurrent mitral valve insufficiency (2 patients). Thromboembolic complications occurred in 2 patients (0.4%), both of whom had a huge enlargement of the left atrium. Of the patients, 88% were much improved functionally, and 86% had a significant radiologic and electrocardiographic improvement. The best results were observed in groups II and III, followed by patients of group I. In 52% of the cases, auscultation was perfectly normal. In 40% there was a minimal or moderate systolic murmur and/or diastolic murmur. In the remaining 8% there was moderate to severe systolic murmur. These residual valvulopathies were recognized soon after operation and remained unchanged thereafter. Only six patients (0.5%) had a recurrent systolic murmur not heard in the immediate post-operative period.

## DISCUSSION AND CONCLUSIONS

The numerous operations proposed between 1957 and 1967 to repair mitral valve insufficiency failed to achieve a predictable result and were associated with a high incidence of recurrent insufficiency.<sup>4, 12, 17</sup> It has been postulated that most of these failures were the result of persistent rheumatic process. In fact, the techniques themselves were to be blamed because of their palliative nature. Narrowing the mitral annulus leads to modification of the anatomy and therefore the physiology of the valve—all the more so since over-correction and even a mild stenosis was considered to be a factor in the success of the technique.<sup>17</sup> Deformation of the annulus and some of the subvalvular lesions which were unrecognized were not treated. The resulting abnormal and limited function of the leaflets led to progressive thick-

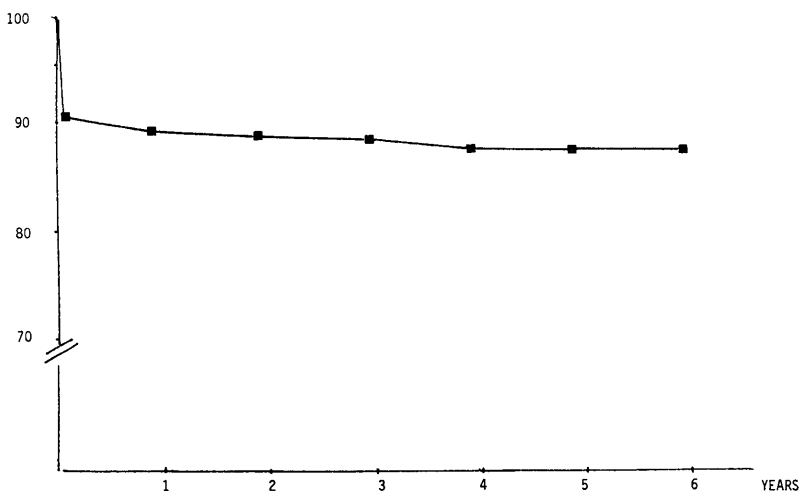


Figure 5. Mitral valvuloplasty survival curve (first 300 cases).

ening and shrinkage. The different techniques presented in this paper and in particular the technique of valvular remodelling using a prosthetic ring<sup>6,7</sup> represent an effort to develop true reconstructive techniques based upon a careful analysis of the lesions and the physiopathology of the orifice.

Several favorable hemodynamic and technical factors become apparent when compared with other techniques: restoration of the normal configuration of mitral annulus, absence of narrowing of the orifice area, respect for the free motion of all the leaflet, prevention of recurrent dilatation of the annulus, accurate treatment of subvalvular lesions.

The clinical results when compared to those obtained with previous methods of valvuloplasty or with valvular replacement are characterized by a low mortality rate, a low complication rate, a good predictability, and stability of the repair.

It must be pointed out that deterioration of an initial good result was exceptional (0.5%), demonstrating the absence of evolution of the rheumatic process. The risk of disinsertion (0.9%) might be reduced in the future by the use of flexible rings.

Thromboembolic complications also were exceptional, in spite of the fact that in most patients anticoagulants were discontinued 3 weeks following operation, the time necessary for the prosthesis to become endothelialized.

The complexity and difficulty of the techniques described above



should not be viewed as a deterrent to the surgeon, because they are commensurate with an improved quality of life for the patient.

## REFERENCES

1. Acar, J., Caramanian, M., Perrault, M., Luxereau, P. and Arnault, J.C. Les insuffisances mitrales par ruptures de cordages d'origine dégénérative. *Arch. Mal. Coeur* 61:1724, 1968.
2. Anderson, A.M., Cobb, L.A., Bruce, R.A. and Merendino, K.A. Evaluation of mitral annuloplasty for mitral regurgitation: clinical and hemodynamic status four to forty-one months after surgery. *Circulation* 26:26, 1962.
3. Belcher, J.R. The surgical treatment of mitral regurgitation. *Brit. Heart J.* 26:513, 1964.
4. Bigelow, W.G., Kuypers, P.J., Heimbecker, R.O. and Gunton, R.W. Clinical evaluation of the efficiency of mitral annuloplasty. *Ann. Surg.* 154:320, 1961.
5. Björk, V.O. and Malers, E. Annuloplastic procedures for mitral insufficiency: late results. *J. Thor. Cardiovasc. Surg.* 48:251, 1964.
6. Carpentier, A. La valvuloplastie reconstitutive. Une nouvelle technique de valvuloplastie mitrale. *Presse Med.* 77:251, 1969.
7. Carpentier, A., Deloche, A., Dauptain, J., Soyer, R., Prigent, C., Blondeau, P., Piwnica, A., and Dubost, C. A new reconstructive operation for correction of mitral and tricuspid insufficiency. *J. Thor. Cardiovasc. Surg.* 61:1, 1971.
8. Dubost, C. Evaluation of surgery for mitral valve disease. *Am. Heart J.* 82:143, 1971.
9. Ellis, F.H., Jr., Frye, R.L. and McGoon, D.C. Results of reconstructive operations for mitral insufficiency due to ruptured chordae tendineae. *Surgery* 59:165, 1966.
10. Gerbode, F., Kerth, W.J., Osborn, J.J. and Selzer, A. Correction of mitral insufficiency by open operation. *Ann. Surg.* 155:846, 1962.
11. Kahn, D.R., Stern, A.M., Sigmann, J.M., Kirsh, M.M., Lennox, S. and Sloan, J. Long-term results of mitral valvuloplasty in children. *J. Thor. Cardiovasc. Surg.* 53:1, 1967.
12. Kay, J.H., Magidson, O. and Meinaux, J.E. The surgical treatment of mitral insufficiency and combined mitral stenosis and insufficiency using the heart-lung machine. *Amer. J. Cardiol.* 9:300, 1962.

13. Lillehei, C.W., Goot, V.L., De Wall, R.A., and Varco, R.L. Surgical correction of mitral insufficiency by annuloplasty under direct vision. *Lancet*, 77:446, 1957.
14. Mac Goon, D.C. Repair of mitral insufficiency due to ruptured chordae tendineae. *J. Thor. Cardiovasc. Surg.* 39:357, 1960.
15. Merendino, K.A., Thomas, G.I., Jesseph, J.E., Herron, P.W., Winterscheid, L.C. and Vetto, R.A. The open correction of rheumatic mitral regurgitation and/or stenosis. With special reference to regurgitation treated by posteromedial annuloplasty using a pump-oxygenator. *Ann. Surg.* 150:5, 1959.
16. Penther, P. Traitement chirurgical par annuloplastie des insuffisances mitrales. Résultats à long terme. *Presse Med.* 77:1885, 1969.
17. Reed, G.E., Tice, D.A. and Clauss, R.H. Asymmetric exaggerated mitral annuloplasty. Repair of mitral insufficiency with hemodynamic predictability. *J. Thor. Cardiovasc. Surg.* 49:752, 1965.
18. Silverman, M.E. and Hurst, J.W. The mitral complex interaction of anatomy, physiology, and pathology of the central valve. *Amer. Heart J.* 76, 399, 1968.
19. Wooler, G.H., Nixon, P.G.F., Grimshaw, V.A. and Watson, D.A. Experiences with the repair of the mitral valve in mitral incompetence. *Thorax* 17:49, 1962.